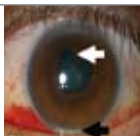
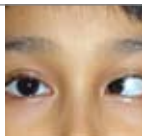
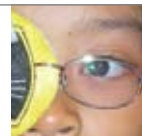3
The Red Eye – when
to suspect uveitis?



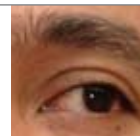
4
Pullout Poster:
Does my child
have a Squint?



6
Refractive Surgery
in Children



7
Exotropia



7 Optometrists' Corner | 8 Quiz

Updates in the Management of Ocular Behçet's

Behçet's disease was first described by Greek physician Adamnatiades in 1931, and later by Turkish Professor Huluci Behçet in 1937, with the classical features of hypopyon, iritis and orogenital ulcers. Since then, it has evolved into a well-recognised clinical entity comprising of a systemic perivasculitis and widespread organ involvement including the eye, integumentary, circulatory and central nervous systems.

The International Study Group for Behçet's Disease established the diagnostic criteria (1990) as recurrent oral aphthous ulcers (Fig 2) plus two of the following: recurrent genital ulcers, ocular inflammation, skin involvement, and/or a positive pathergy test. Inflammatory eye disease occurs in approximately 70% of all patients, and is typically preceded by the onset of oral ulcers. However, the delay between symptoms may be as long as 14 years and in 10% of patients, ocular inflammation is the presenting feature. Most have bilateral although possibly asymmetrical involvement, and only 6% of cases are unioocular (Fig 1, 3, 4a and 4b).

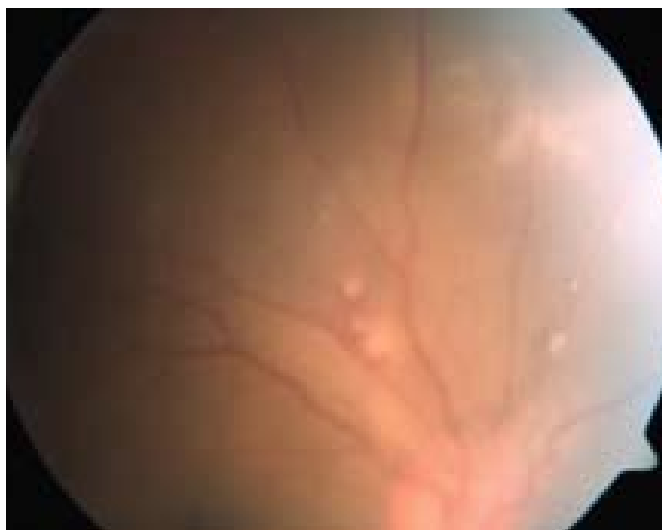

Fig 1. Peripheral vasculitis with cotton wool spots and vitritis.

Dubbed the "Silk Road Disease" due to its unique distribution in countries between the Mediterranean and the Orient, the pathophysiology of Behçet's is largely unknown although associations with HLA-B51 and infections have been proposed. Over the last 2 decades, the role of neutrophil hypersensitivity and cytokines, including TNF α , interleukin-1 β , IL-8 and more recently IL-17 has become increasingly recognized. This has led to significant changes and evolution in the management and prognosis of the disease.

Visual prognosis of ocular Behçet's with recurrent posterior segment vasculitis prior to modern treatment regimes was bleak and 20-50% became blind within 5 years through inflammatory retinal vein occlusions and cystoid macular oedema. Other causes of visual loss include cataract, macular scar formation and optic nerve disease.

Traditionally, corticosteroids are the first-line and mainstay of treatment. High-dose corticosteroids are effective (Toker et al) in controlling acute, vision-threatening posterior uveitis attacks. Typically 1g methylprednisolone is administered intravenously for 3 days followed by oral prednisolone (1 mg/kg/day), which is gradually tapered over 6-12 weeks. For frequent refractory attacks, Ohguro et al used repeated intravitreal corticosteroids to prevent recurrence. However the myriad side effects of long-term high-dose corticosteroids have prompted the use of steroid-sparing agents.

According to IUSG guidelines, immunosuppressive therapy is considered absolutely required to achieve long-term control. Unfortunately, no single combination of drugs has been shown to be uniformly useful with treatment often limited by side effects. Common choices include an anti-metabolite (e.g. azathioprine, mycophenolate mofetil) combined with a calcineurin inhibitor (e.g. cyclosporine A, tacrolimus). Chlorambucil was the first cytotoxic drug to be used in the 1970s, but this was limited by profound bone marrow toxicity. As such, chlorambucil and cyclophosphamide are now reserved for refractory cases; alas up to 15% of ocular Behçet's remains refractory to monotherapy with alkylating agents. Akman-Demir et al recently identified an association between cyclosporine and an increased risk of parenchymal neurological disease.

Continued next page



Chief Editor's Message

Dear Readers,

This issue was produced in the wake of NHG Eye Institute's 3rd International Ophthalmology Congress (IOC), which was held in November 2010 at Suntec Singapore International Convention & Exhibition Centre.

The highly successful Congress saw over 400 attendees and focused on Cornea, Refractive Surgery and Paediatric Ophthalmology. One of our articles, "Refractive Surgery in Children", touches on a highly controversial issue that sub-specialists in these two fields are grappling with today.

Elsewhere in this issue, we deal with far more conventional facets of children's eye diseases, in particular strabismus; our optometrist also weighs in with a set of practical tips on how to best evaluate the vision of a struggling, easily distracted kid. We also hope the patients in your waiting room will find the pull-out poster on squints a worthwhile read.

The other sub-specialty receiving the spotlight this round is uveitis, and the articles also run the gamut from the pragmatic (how to recognise it) to the more esoteric (Ocular Behçet's Disease).

My team and I wish you all the best for 2011 and may you find this issue of FOCUS useful and informative.

Best Regards

FOCUS Editorial Team

Dr Wong Hon Tym (Chief Editor)
Dr Jeanne Joyce Ogle (Editor)
Ms Tan Mui Leng (Secretariat)
A/Prof Goh Lee Gan (Advisor)

We would appreciate your frank feedback on any part of this newsletter, be it on the format or content. Please email your comments to tei@nhg.com.sg or mail to Ms Tan Mui Leng, NHG Eye Institute @ Tan Tock Seng Hospital, 11 Jalan Tan Toc kSeng, Singapore 308433. Please indicate if you would grant us the permission to publish your letter. If you would like to receive our 4 onthly-newsletter, please send an email with your name to tei@nhg.com.sg with the subject heading 'FOCUS Subscribe'.

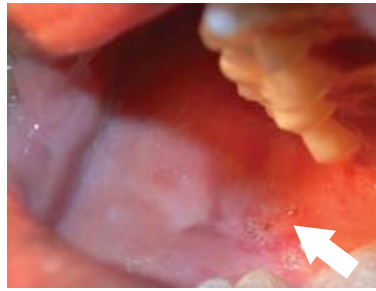

Fig 2. Typical mouth ulcers in Behçet's disease (white arrow).

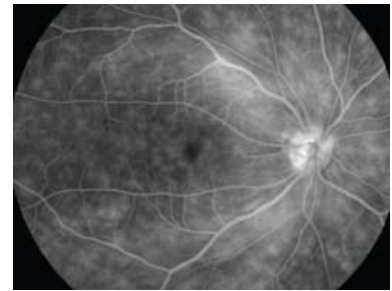


Fig 3. Fluorescein angiogram showing retinal vasculitis and patchy capillary non-perfusion.

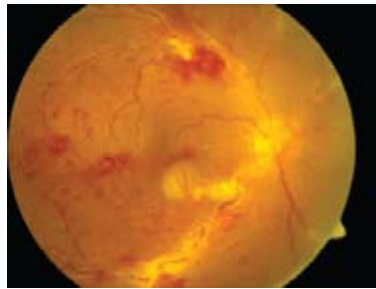


Fig 4a. Extensive retinal vasculitis with venous and arterial occlusion.

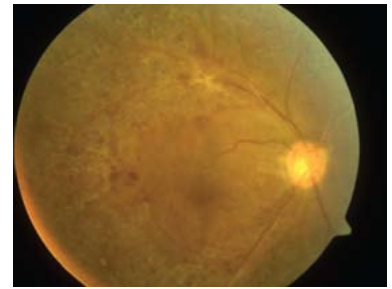


Fig 4b. The same patient after immunosuppression and panretinal photocoagulation, showing resolution of retinal vasculitis and stabilisation of neovascularisation.

Fortunately, knowledge of the immunopathology of Behçet's has allowed newer, targeted interventions. Blockade of TNF α with infliximab, a chimeric anti-TNF- α monoclonal antibody, effectively reduces the severity of systemic and ocular Behçet's with 6-8 weekly infusions of 3-5 mg/kg typically resulting in rapid control of inflammation. Yamada et al (2010) showed that infliximab was more effective than cyclosporine in reducing the acute episode of Behçet's-related uveitis. However the lack of sustained remission, potential side effects of tuberculosis reactivation, lymphoma and progressive multifocal leukoencephalopathy, as well as potential resistance after prolonged treatment may limit its use. In such cases, reports of successful switching to high dose subcutaneous adalimumab, a humanized monoclonal anti-TNF antibody, have been reported.

Kötter and Demiroglu et al showed the usefulness of subcutaneous recombinant human interferon α -2- α (rhIFN α -2 α). Up to 90% of cases responded to therapy but more importantly, it was the first agent reported to achieve long-term remission after cessation of treatment.

In the last 5 years, a new class of T-cells, Th17, has been found to play an important role in mediating the initiation and maintenance of a wide range of autoimmune and inflammatory conditions via IL-17, a proinflammatory cytokine that is upregulated in Behçet's disease. A multi-center phase III trial is currently underway to evaluate subcutaneous anti-IL-17. NHG Eye Institute @ Tan Tock Seng Hospital is participating in this pivotal trial.

Currently, most uveitis centres adopt a step-ladder treatment algorithm with multiple immunosuppressive agents. While appropriate for most patients, irreversible vision loss may still occur. There is increasing evidence for the early use of biologics and their superiority over conventional therapeutics - a paradigm shift that may well prevent the devastating blindness of this disease.

By Dr Stephen Teoh, NHG Eye Institute@TTSH

The Red Eye – when to suspect uveitis?

The red eye is one of the most common presenting symptoms in ophthalmology and can be caused by a number of conditions. It is therefore important to differentiate between benign and self-limiting causes such as conjunctivitis, and possibly sight-threatening conditions such as acute angle closure glaucoma, infective keratitis, uveitis or endophthalmitis.

The term **uveitis** refers to inflammation of the uveal tract, which includes the iris, ciliary body and choroid. It most commonly affects individuals between the ages of 20–50 years, but can occur at any age, with an annual incidence of 14 – 17 per 100,000. It is the fifth commonest cause of visual loss in developed countries.

Uveitis can be classified anatomically into:

- *Anterior uveitis* – inflammation of the iris and anterior chamber
- *Intermediate uveitis* – inflammation of the ciliary body, pars plana and anterior vitreous
- *Posterior uveitis* – inflammation of the retina and choroid, and
- *Panuveitis* – inflammation of all the layers of the uveal tract.

Most commonly idiopathic in nature, it may also be **caused** by infectious diseases, or may be associated with autoimmune and systemic inflammatory diseases, and neoplasms (masquerade syndrome).

In general, one should suspect uveitis when the clinical features include the following:

Symptoms:

- Dull, aching pain
- Photophobia
- Blurred vision
- Floaters – due to vitritis
- Photopsia – may be a feature of posterior uveitis

Signs:

- Redness which is mainly circumcorneal, with minimal or no discharge or conjunctival follicular reaction. Involvement is mainly unilateral
- Anterior chamber cells, flare and hypopyon (Fig 1)
- An irregular pupil due to posterior synechiae (Fig 1), which reacts poorly to light
- The cornea is usually clear, but clumps of inflammatory cells (keratic precipitates) (Fig 2) may deposit on the endothelial surface, especially inferiorly
- Iris nodules

Specific questions to ask uveitis patients include:

- *Ocular history* – previous similar episodes, trauma and previous surgery.
- *Systemic review* – a history of back stiffness, arthritis, rashes, urinary symptoms, recent insect bites, sexually transmitted diseases (STDs) and tuberculosis (TB) exposure may help in identifying the underlying cause, if any.

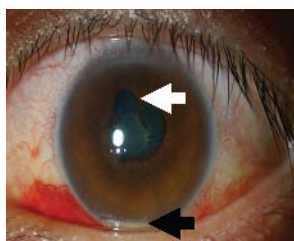


Fig 1. Posterior synechiae (white arrow) and hypopyon (black arrow).

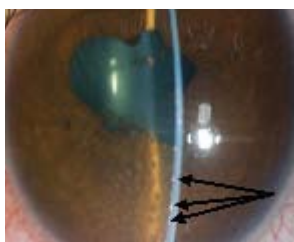


Fig 2. Keratic precipitates (black arrows).

By Dr Alex Lau, NHG Eye Institute @ TTSH

SPOTLIGHT ON

NHG Eye Institute’s Uveitis Team




Dr Lim Wee Kiak

Trained in the world renowned National Eye Institute, National Institutes of Health, USA in 2003, Dr Lim Wee Kiak, Member of Parliament, heads NHG Eye Institute’s Ocular Inflammation, Immunology and Uveitis Service. He is a leading expert in the field and has authored 26 peer-reviewed publications and 9 book chapters. He is also a member of the International Uveitis Study Group (IUSG), International Ocular Inflammation Society (IOIS) and American Uveitis Society (AUS).



Dr Stephen Teoh

Dr Stephen Teoh completed his HMDP Fellowship at the Bristol Eye Hospital, UK, under the mentorship of Professor Andrew Dick in 2006. He undertook training in both vitreoretinal surgery and uveitis. This was followed by a clinical observership in HIV-related ocular inflammation at the Wilmer Eye Institute, Johns Hopkins Hospital, USA. Dr Teoh runs his dedicated sub-specialty clinics at NHG Eye Institute @TTSH, as well as the Communicable Disease Centre (CDC). Over and above his twin sub-specialties, Dr Teoh also oversees research facilitation in the Institute.



Dr Ho Su Ling

Dr Ho Su Ling received her undergraduate medical training in the Royal College of Surgeons in Ireland. She completed her ophthalmology basic and advanced surgical training programme in Ireland and was awarded the Registrar’s Prize by the Royal Academy of Medicine in Ireland and the Barbara Knox Medal by the Irish College of Ophthalmologists. She was fellowship-trained in uveitis by Professor John Forrester, University of Aberdeen, Scotland and was instrumental in setting up the uveitis database in the clinics there. Her current projects include looking into pseudoexfoliation syndrome in the Asian population and the planning of electronic medical records (EMR) for NHG Eye Institute.

Refractive Surgery in Children

Refractive errors are an important cause of visual impairment and amblyopia in children. Although **spectacles** are the most commonly used treatment method, some children may not tolerate spectacles due to social stigma, a narrowed field of view, and prismatic induced aberrations in high ametropia, especially in peripheral gaze. High degrees of aniseikonia may also impede the development of binocular vision.

Contact lenses, on the other hand, have the advantage of better contrast sensitivity and improved quality of vision, especially in patients with high ametropia. In addition, they provide a larger field of vision and reduce aniseikonia because of their proximity to the corneal surface. However, challenges and risks of contact lenses in children include difficulty with insertion and removal, infection, intolerance to extended wear and expense.

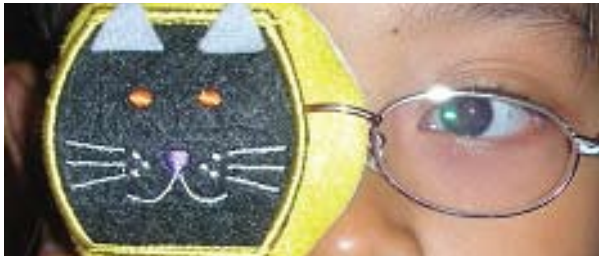

Fig 1. A child with myopic anisometropia and left amblyopia

Refractive surgery in children has been proposed as an alternative in the literature. LASIK, LASEK, and PRK have been used to treat patients from the age of 0.8 years with severe myopic anisometropia (Fig 1), with many achieving improved binocular vision. High bilateral myopia of up to $-11.5D$ has also been treated, with an upper limit of $-12D$ due to the risk of ectasia. These procedures have also been used for hyperopic anisometropia and less commonly accommodative esotropia (Fig 2) in children and adolescents. However, almost 50% of accommodative esotropia patients required re-operation for undercorrection in one series.

Overall, the procedures were found to be relatively safe with most developing only mild corneal haze and occasional complications such as flap dislocation. Higher degrees of myopia are known to be

associated with greater corneal haze and although mitomycin C use lessens the degree of haze in adults, its effect on children remains to be investigated.

The choice of refractive procedure depends on clinical situation and surgeon preference. LASIK advocates argue that PRK, especially in higher myopes, carries a high risk of myopic regression and corneal haze due to ablation of the Bowman layer. PRK may also require longer term steroid use with concomitant risk of cataracts and glaucoma. In contrast, PRK advocates argue that the risk of LASIK flap dislocation in children prone to eye rubbing and trauma outweighs the risks posed by PRK. PRK also reduces or avoids other LASIK-related complications, including flap tear or striae and keratectasia. Intraocular refractive surgery can be considered in patients with high ametropia who are not candidates for LASIK or PRK.

Phakic IOL implantation and clear lens extraction with IOL implantation has also been reported in children aged 1 to 18 years with preoperative refractive errors of -12.5 to $-26 D$. Complications include IOL dislocation, retinal detachment, and posterior capsular opacity. However, paediatric patients have a higher risk of cataract and glaucoma after such procedures because of their smaller anterior chambers compared with adults as well as their propensity for eye rubbing. Furthermore, eye growth can affect the stability of the lens with other potential future problems.

Other specific challenges include the nature of the changing refractive error in children, the need for anaesthesia, a greater susceptibility to trauma in children with possible flap dislocation, the lack of normograms and evidence supporting long-term safety, uncertain laser centration because the child cannot fixate, and possible alteration of laser function in the presence of inhalational anaesthetics.

In conclusion, refractive surgery in children is still considered controversial and should be used judiciously for selected patients who are intolerant to, or have failed, conventional therapy.

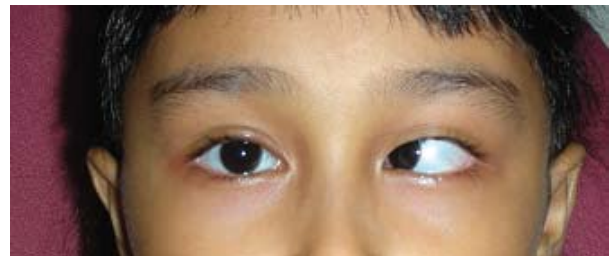

Fig 2. A child with accommodative esotropia

By Dr Leo Seo Wei, NHG Eye Institute@TTSH

SPOTLIGHT ON

NHG Eye Institute's Paediatric Ophthalmology Team



Dr Leo Seo Wei

Dr Leo Seo Wei heads the Paediatric Ophthalmology and Strabismus Service at NHG Eye Institute and oversees TTSH's Children's Eye Centre and Eye Alignment Centre. Her interests are strabismus surgery (adult & paediatric), refractive errors and learning disabilities in children. She completed 2 fellowships in the USA. The first was an American Association of Pediatric Ophthalmology & Strabismus-accredited clinical fellowship at the University of Michigan and W.K Kellogg Eye Center, Ann Arbor, under the tutelage of Prof Monte Del Monte and Prof Steven Archer. This was followed by a stint with Dr Kenneth Wright in Los Angeles. She has since published numerous peer-reviewed articles and presented at international conferences.



Dr Lim Su Ann

Dr Lim Su Ann, a neuro-ophthalmologist at NHG Eye Institute@TTSH and Visiting Consultant to KK Women's and Children's Hospital, has a special interest in paralytic strabismus and motility problems of neurologic origin in both adults and children.



Dr Foo Fong Yee

Dr Foo Fong Yee is a recently promoted Associate Consultant at NHG Eye Institute, with an interest in paediatric ophthalmology and strabismus. She is also an appointed Clinical Tutor with the Yong Loo Lin School of Medicine, Singapore.

Visiting Consultant

Dr Benjamin Chang, NHG Eye Institute@TTSH

Exotropia

Exotropia is a horizontal misalignment of the eyes where one eye is turned outwards (Fig 1). This is the most common type of squint seen in Singaporean children. It usually presents between the ages of 2-4 years with deviation occurring intermittently, especially when the child is tired, ill, distracted or daydreaming. The child may close one eye, especially in bright sunlight. Often, it is more noticeable when the child looks into the distance. Over time, the deviation may manifest more frequently and become constant.

Management of Childhood Exotropia:

1. Spectacles

For significant refractive errors such as myopia or astigmatism, prescribing glasses may aid in control as clearer vision can help stimulate fusion. In addition, giving myopic correction ensures that the child accommodates more for near and intermediate targets, and this accommodative convergence can help maintain alignment.

2. Orthoptics

For patients with concurrent convergence insufficiency, exercises to improve convergence (e.g. pencil push-ups) can help in controlling intermittent exotropia. These are taught to the child and parents, and can be performed at home. Other orthoptic exercises include stereogram exercises, prism exercises and fusional vergence training programmes.

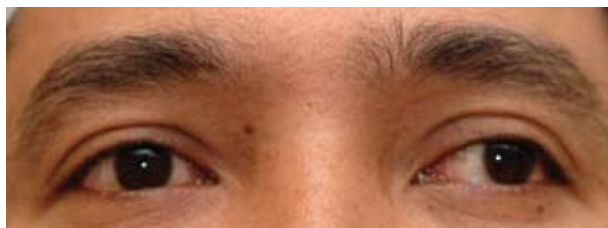

Fig 1. Left exotropia (divergent squint). Note the medially displaced corneal light reflex.

If unilateral amblyopia is present, then patching of the dominant eye is warranted.

3. Surgery

The majority of children with significant exotropia will eventually need alignment surgery. Indications include noticeably manifest deviation more than 50% of the time and deteriorating stereoacuity. Depending on the size and nature of the deviation, squint surgery (Fig 2) may involve weakening of one or both lateral recti (recession) and/or strengthening of one or both medial recti (resection). Surgical alignment can also be done at any stage in adulthood.

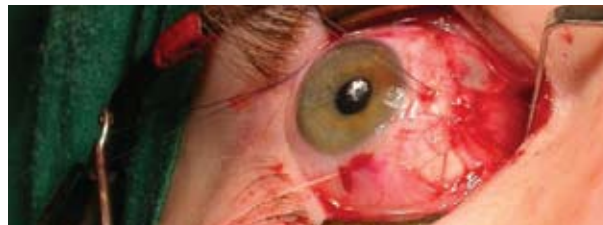

Fig 2. Squint surgery. Here, the medial rectus has been exposed and isolated.

Other exotropias:

- 1. Congenital exotropia** is very uncommon, and is usually associated with other neurological abnormalities. Treatment is mainly surgical.
- 2. Sensory deprivation exotropia** occurs as a result of prolonged poor vision in one eye, eg. patients with unilateral cataract. Binocular vision is disrupted and the eye may progressively deviate outwards. Removal of the cause of poor vision (e.g. cataract surgery) may restore binocular vision and stimulate ocular re-alignment. Otherwise, squint surgery can be performed.

By Dr Benjamin Chang,
Visiting Consultant to NHG Eye Institute@ TTSH

Basic Strategies for Paediatric Vision Screening

Vision screening for children can lead to early detection and treatment of alignment and acuity problems, and can thus often prevent permanent impairment of vision.

Unfortunately, assessing a child's vision is often a daunting task, requiring time, patience and understanding. The following strategies may thus be helpful in enhancing the assessment.

1) An appropriate clinical environment:

The clinical setting should not be congested so as to avoid distraction. Materials should be prepared and assembled prior to the assessment to avoid delays during testing given the short attention span of most children.

2) Create rapport with the parent's help:

The child should be at ease and it is often reassuring to have them sit on their parent's lap. Clinical procedures may be explained to parents so that they can demonstrate the anticipated testing procedures to their child.

3) Be competent in testing procedures:

Objective examination procedures should be chosen according to the child's age, abilities, knowledge and experience.

For instance, a pre-verbal child requires preferential-looking techniques to assess their acuity. Kay's pictures with or without matching cards may be used if the child is able to recognize and describe pictures or basic symbols.



When testing ocular alignment, the cover test may be difficult or unreliable if the child is unable to comply with fixation. In such cases, other methods such as the Krimsky's corneal reflection technique may be used to determine the magnitude of deviation.

4) Use of Interesting Objects:

Colourful, noise-making toys may be used to gain the child's attention, and these are particularly useful when testing ocular alignment. A moving stimulus or cartoons are great targets to obtain steady fixation.

5) Verbal communication skills:

Good verbal communication is of paramount importance to improve the quality of the patient-practitioner relationship and it is essential to give simple instructions and explanations. Repetitive encouragement and tangible rewards to the child are highly recommended as this potentially encourages the child's compliance.

By Ms Lau Wei Yee, NHG Eye Institute@ TTSH

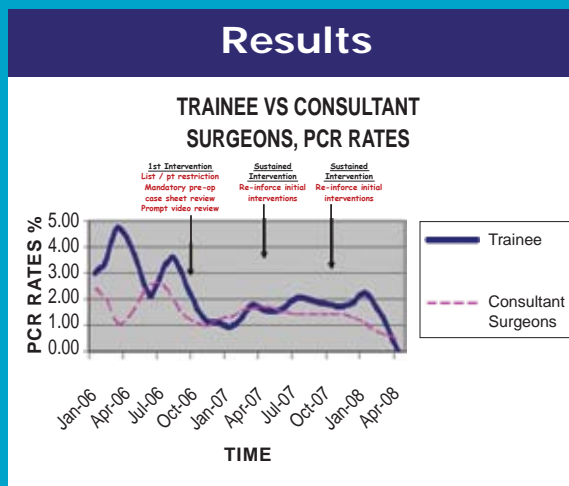Spotlight On NHG Eye Institute Quality Day Projects

Striving for high-quality clinical outcomes is a key objective. From the 10 projects presented at our Quality Day in April 2010, we feature two outstanding efforts, both of which have been published in peer-reviewed journals.

1. MAXIMISING SAFETY OF CATARACT SURGERY TRAINING By Dr E-Shawn Goh

A clinical department's commitment to a robust cataract training programme need not be at odds with the commitment to maximising outcomes. This Clinical Process Improvement Project (CPIP) developed modifications to our cataract training program, and tested them in a controlled, interventional case series to evaluate their effect on the posterior capsule rupture (PCR) rate in trainee surgeons. Data collection and interpretation was prospective and blinded.

Prior to intervention, the PCR rate for trainees was 3.34% compared to 1.89% for trained surgeons ($p < 0.017$). Multiple interventions such as stringent case selection, mandatory pre-operative case sheet review, and prompt video review of complications were introduced and enforced, to maximise cataract surgery training safety. The 19-month follow-up



data showed a statistically significant reduction in trainee PCR rates (1.53%, $p < 0.007$, Wilcoxon signed rank test) compared to trained cataract surgeons (1.23%, $p < 0.285$).

Limitations included using trained cataract surgeons as controls. In addition, multiple interventions were simultaneously instituted, making identification of a single influential factor impossible to identify.

Published in International Journal of Health Care Quality Assurance, 2009.

2. REDUCTION IN LENGTH OF HOSPITALISATION FOR MICROBIAL KERATITIS PATIENTS By Dr Jimmy Lim

Co-authors: Barkham T, Ming CQ, Lim L, Lin J, Hong GL, Jin HW

Prolonged hospital stays for microbial keratitis patients are a burden to the resources of a multi-disciplinary tertiary hospital. We evaluated the impact of streamlining workflow and increasing cross-disciplinary interactions on the average length of stay, speed of initiation of therapy, microbial culture positive rate, patients' satisfaction and resource savings. An ophthalmologist, microbiologist, pharmacist and nursing staff came together to brainstorm, identify areas for improvement, and formulate a new workflow protocol.

After an initial test, the new workflow was implemented, including improved communication with the microbiologist, standardization of corneal scraping techniques, increased frequency of review by a cornea subspecialist and decreased lag time in starting induction dosages of antibiotics. All these measures were applied for a period of 1 year and the average length of hospitalisation was successfully reduced from 7.4 to 5.65 days (22% reduction). There was an improvement in microbial keratitis culture positive rate from 51% to 74%, the average time taken to initiate antibiotic eye drops after first contact with the doctor was 26 minutes, and 74.4% of the patients surveyed were satisfied with the length of stay. This proved that a reduction in average length of stay can be achieved by strict adherence to a formulated workflow and coordinated cross-disciplinary interactions, thus enabling more effective and efficient treatment for microbial keratitis inpatients.

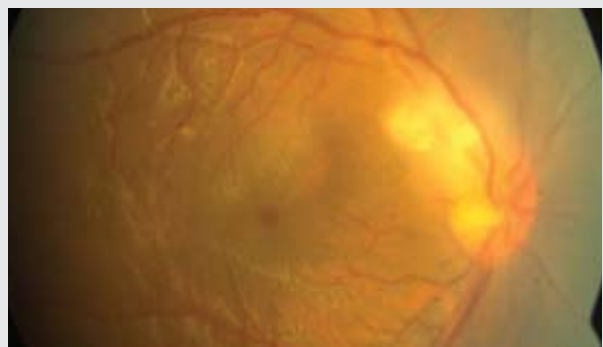
Published in International Journal of Health Care Quality Assurance, 2009.

TEST YOUR EYE Q QUIZ

A 17-year-old male presented with a 5-day history of redness, blurred vision and floaters in the right eye. He denied any recent trauma and did not have any systemic complaints.

On examination, his visual acuity was 6/9 in the right eye. Anterior segment examination was essentially normal. However, retrolental cells were noted in the right eye and the right fundus photo is shown as follows (please see figure on the right).

1. What is the diagnosis?
2. What investigation would you order?
3. How would you treat this patient?
4. What is the prognosis?



By Quiz Master: **Dr Alex Lau**, NHG Eye Institute @ TSH
 develop permanent visual disability.
 4. Recurrence is common (~80% at 5 years). Individuals with recurrent disease are more likely to
 Systemic treatment includes pyrimethamine, sulfadiazine, clindamycin, bactrim or atovaquone,
 and corticosteroids
 d. Any lesion in an immuno-compromised individual
 c. Marked vitritis
 b. Lesions threatening a major vessel

Answers:
 1. Ocular toxoplasmosis. There is a pale patch of retinitis contiguous with the superior
 portion of the disc.
 2. Serum anti-Toxoplasma immunoglobulin (IgG) (Note: Ocular toxoplasmosis is essentially
 a clinical diagnosis)
 3. As ocular toxoplasmosis is self-limiting in immuno-competent individuals, treatment is
 only required for:
 a. Lesions involving the optic disc or macula

Does my child have a Squint?

What is a squint?

A squint (strabismus) is a misalignment of the eyes such that both eyes do not look together in the same direction. When one eye is looking straight at an object, the other eye may turn inwards, outwards, upwards or downwards.

Squints are common, affecting 5% of children, and can also develop later as an adult.

What causes squints?

- Refractive errors & focusing problems
- Poor vision
- Familial / Genetic
- Thyroid problems
- Muscle problems (eg. myasthenia gravis)
- Rarely, more serious problems within the eye (eg. cancer of the eye), the brain or the nerves involved in moving the eyes

What are the danger symptoms and signs?

- Squints that develop suddenly
- Double vision
- Poor vision
- Reduced eyeball movement
- A white pupil
- Ptosis (droopy eyelid)
- Other neurological symptoms such as headache, nausea or vomiting

Does my child have a squint?

Squint may be suspected if your child has any of the following:

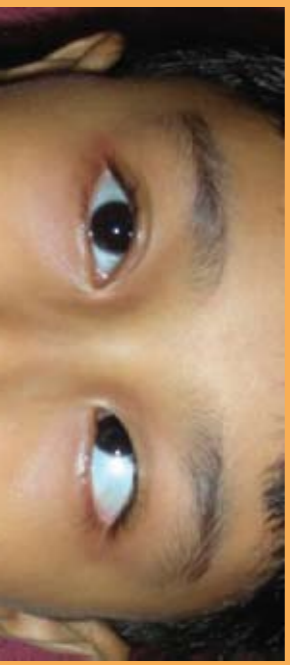- Either eye is observed to turn either towards or away from the nose
- An abnormal head posture such as a head tilt, face turn, chin up or chin down posture
- Other symptoms - frequent blinking, tired eyes and photophobia (avoidance of bright lights)

The presence of a squint in a child is best determined by an eye specialist.

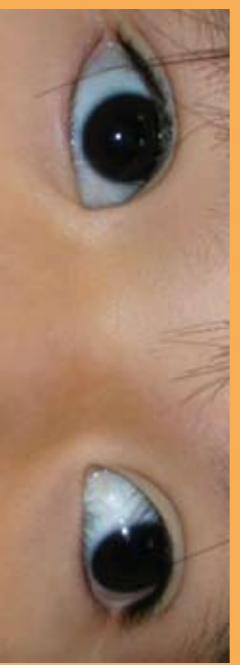How is a squint treated?

Treatment depends on the type, nature and cause of the squint. Aims are to restore alignment of the eyes, and improve 3-dimensional perception and vision.

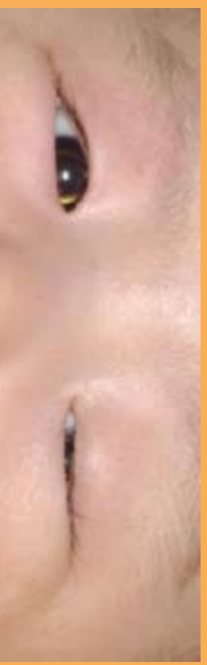Squints can be treated with glasses, eye patching and eye muscle exercises. In some children, surgery on the eye muscles may be required.



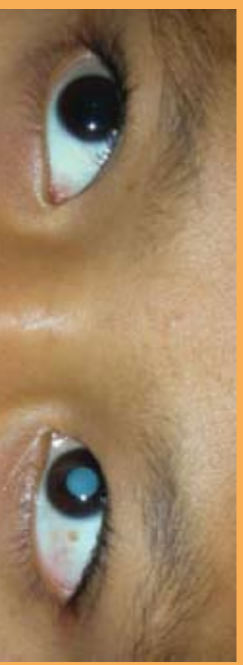Left esotropia (inward turning of the left eye)



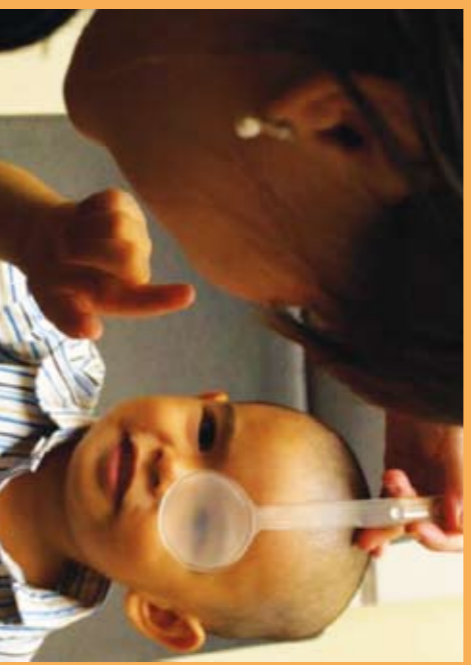Left exotropia (outward turning of the left eye)



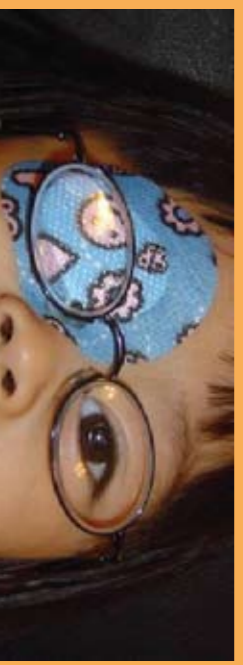Droopy left eyelid



A white pupil in the left eye



Examination by an eye specialist



Eye patching for children with squints

Consult your family doctor or an eye care professional if in doubt.